

Repair of cutaneous wounds with the use of low cost surgical glue *

Reparo de feridas cutâneas usando cola cirúrgica de baixo custo

Sandro Cilindro de Souza¹

Carlos Briglia²

Sérgio Ricardo Matos Rodrigues da Costa³

Abstract: BACKGROUND: The advantages of the cyanoacrylates in cutaneous synthesis have been often demonstrated in the literature. However, these products have been underutilized in Brazil due to the high costs of the 2-octil-cyanoacrylate. Besides, few studies have been done with the more economically accessible form, the 2-ethyl-cyanoacrylate, as a cutaneous tissue adhesive.

OBJECTIVE: To evaluate the effectiveness of the closing of cutaneous lesions using ECA.

METHOD: This was a prospective study in which 46 wounds were occluded using the low cost ECA as an alternative to intradermal suture.

RESULTS: Excisions (97,8%) and traumatic wounds (2,2%) were treated with 2-ethyl-cyanoacrylate and deep relaxed sutures as synthesis method. Unaesthetic scars (22%), infection (2,1%), dehiscence (2,1%) and contact allergic dermatitis (2,1%) were the problems we found. There were no cases of necrosis or keloids. The results were considered satisfactory in most cases (97,3%).

CONCLUSIONS: The use of 2-ethyl-cyanoacrylate was shown to be safe and with satisfactory cosmetic results in this group of patients.

Keywords: Cyanoacrylates; Suture techniques; Tissue adhesives

Resumo: FUNDAMENTOS: As vantagens dos cianoacrilatos em síntese cutânea têm sido sobejamente mostradas na literatura. Entretanto, estes produtos têm sido subutilizados no Brasil devido aos elevados custos do 2-octilcianoacrilato. Ademais, a forma mais economicamente acessível, o 2-etilcianoacrilato, tem sido pouco estudada como adesivo cutâneo.

OBJETIVO: Avaliação da eficácia do fechamento de lesões cutâneas usando o 2-etilcianoacrilato.

MÉTODO: Estudo prospectivo no qual 46 feridas foram ocluídas usando o 2-etilcianoacrilato de baixo custo como alternativa a sutura intradérmica.

RESULTADOS: Feridas excisionais (97,8%) e traumática (2,2%) foram tratadas com 2-etilcianoacrilato e suturas profundas relaxadoras como método de síntese. Cicatrizes inestéticas (22%), infecção (2,1%), deiscência (2,1%) e dermatite alérgica de contato (2,1%) foram os problemas encontrados. Não houve casos de necrose ou quelóides. Os resultados foram considerados satisfatórios na grande maioria dos casos (97,3%). Conclusões: O uso do ECA mostrou-se seguro e com resultados cosméticos satisfatórios neste grupo de pacientes.

Palavras-chave: Adesivos teciduais; Cianoacrilatos; Técnicas de sutura

Received on 01.12.2010

Approved by the Advisory Board and accepted for publication on 25.04.2011

* Work performed at the Hospital Geral de Camaçari – Camaçari (BA), Brazil.

Conflict of interest: None

Financial funding: None

¹ Plastic Surgeon at the Clinic of the Faculdades Adventistas da Bahia (FADBA) – Cachoeira (BA), Brazil.

² Plastic Surgeon at the Hospital Geral de Camaçari – Camaçari (BA), Brazil.

³ PhD in Medicine by the Universidade Federal da Bahia (UFBA) – Assistant Professor in Biophysics at the Universidade Federal da Bahia (UFBA) – Salvador (BA), Brazil.

©2012 by Anais Brasileiros de Dermatologia

INTRODUCTION

Since the last decade of the past century, synthetic adhesives have been tested for medical application. Currently the most used one for cutaneous closing are the cyanoacrylates (CAs). In a spontaneous exothermic reaction, these substances are polymerized from a monomer, the cyanoacrylic ester $\text{CH}_2=\text{C}(\text{CN})\text{COO-R}$. The resulting film connects the adherents like a bridge. The most important chemical characteristic of the CAs is the ability to quickly form strong bonds that progressively increase in intensity over the 48 hours following the application. The CAs constitute an interesting synthesis method, as they do not damage the tissues and eliminate the need for sutures.^{1,2}

The advantages of the CAs in cutaneous synthesis have been vastly shown on the literature.² However, these products have been underutilized due to the high cost of the surgical adhesive almost exclusively nowadays, the 2-octilcianoacrilato (Dermabond®, Summerville, NJ). Besides, the more economically accessible form, the 2-etilcianoacrilato (ECA, Aron Alpha, Permabond, Krazy glue, Superbond®, Epiglu®) have been little studied as a cutaneous adhesive.¹⁻³

The objective of this study is to evidence the efficacy of the use of the ECA in the closure of cutaneous excisions as an alternative to suture.

METHODS

This prospective study was performed during the period of June 2005 to April 2010. All patients seen at the plastic surgery outpatient's clinic, regardless of sex and age, with superficial cutaneous lesions with indication for excision and repair by primary closure were included. Individuals with clinical or laboratorial evidence of previous allergy to the components of the surgical adhesive formula, blood dyscrasias, use of immunosuppressant drugs, with diabetes mellitus, alcoholism, protein-caloric malnutrition and severe vitamin deficiency, coronary disease, hyperthyroidism, psychopath, and emotional instability were excluded. Also excluded were lesions located in moist (axilla, perineum and mucosa-cutaneous junctions), edematous, infected or inflamed areas. And finally, the refusal by the patient in participating in the research was also an exclusion criterion, as well as the refusal to sign the Free and Explained Consent Form.

Surgical technique. Antisepsis was done with clohexedine 0,5% alcoholic solution, followed by placement of sterile surgical pads. Anesthesia was done by perilesional infiltration of 0,5% lidocaine with 1:100.000 vasoconstrictor.

The surgical event comprised of the following stages:

1. Elliptical surgical excision two to three times longer than the diameter of the lesion and extending 3 mm laterally beyond its borders (Figure 1).

2. Rigorous hemostasis by digital compression and electrical cauterization.

3. Suture in two levels: 1st: subdermal, with simple inverted stitches involving the deep dermis, separated by intervals of approximately 0,5 cm, 2nd: dermal, by continuous intradermal suture.

4. Gluing of the external surface of the epidermis by spreading two drops of ECA at each 2,5 cm of the closure, without allowing the product to leak into the suture line, so as to form two juxtaposed fine films over an extension of 1 cm laterally to the suture line. We waited two minutes for the polymerization of each cyanoacrylic film. Next, the intradermal suture was removed.

Dressings or prophylactic antibiotics were not used. Digital photographs were taken for surgical documentation.

Post-operative. The patients were released immediately and were instructed to use a micro porous tape over the scar as soon as it was completely closed and free of scabs, for a period of 3 months. The follow up was done by a weekly consultation over the following 21 days and a final assessment at 3 months. On the third month assessment photographs were taken for comparison with those taken pre-operatively. At this moment the patients were asked if they were satisfied with the results of the surgery.

RESULTS

The characteristics of the studied population and the technical details of the procedure can be seen on table 1.

Graphs 1 to 4 and figures 2 to 4 show the results obtained, the incidence of complications and the aesthetic results according to the record of the patients' personal satisfaction.

DISCUSSION

ECA as a tissue adhesive has been used with satisfactory results in dentistry, abdominal surgery, gynecology, gastroenterology, neurosurgery, maxillary surgery, orthopedics, plastic surgery, urology, vascular surgery, cardiac surgery, thoracic surgery and forensic medicine.¹⁻⁶ Nevertheless, the gluing of excisional wounds using ECA has not yet been described as a synthesis modality.²

Many problems have been attributed to ECA as a cutaneous adhesive, which have made its acceptabi-

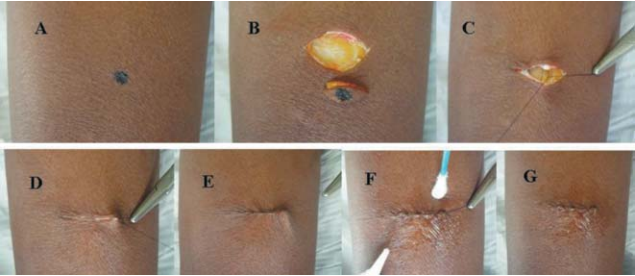


FIGURE 1: Surgical technique. A: nevus on the lateral aspect of the left arm, B: elliptical excision, C: inverted single stitch of subdermal suture, D: end of subdermal suture, E: end of intradermal suture, F: radial spreading of the ECA with cotton bud, G: end of skin gluing; note removal of intradermal suture and transparent and wrinkled aspect of the acrylic film

lity difficult. Studies with ECA show that the product is not carcinogenic.⁵ Acute and chronic inflammation, seroma, *in vitro* cytotoxicity, necrosis, leukonychia and allergic contact dermatitis are other problems linked with the use of ECA on the skin.^{1,7,8} However, these studies have few cases and thus deserve additional assessment. Besides, other works which have confirmed adverse effects with the use of CAs on the skin are limited to minor local complications, specially inflammation and partial dehiscence, and are probably due to the surgical acts themselves and not to the specific use of the adhesive.^{2,4,9}

Many authors have shown that the main disadvantage of the CAs is the cyto-histotoxicity, which manifests itself by means of *in vitro* cellular lyses and *in vivo* formation of acute or chronic inflammatory

reactions.^{2,5} The question of toxicity came up on the medical arena with the initial application of CAs for gluing nerves, tendons, bones, lungs, blood vessels and skin.¹⁰ The toxicity is attributed to the metabolization with the liberation of degradation products (formaldehyde and acetate). The shorter chain derivatives have shown more toxicity than the ones with longer chains, because they degrade faster. The ECA has shown to generate a smaller histotoxic reaction in relation to the other CAs with short chain.^{4,5} The intensity of the inflammation triggered by the CA does not seem to affect its tensile strength.¹ The histotoxic effect is more pronounced in deep and well vascularized tissues, and so the use of the CAs has been recommended for avascular surfaces like the skin.⁴ Despite recent advances, the problem persists, and the use of the CAs is not free from risks.^{1,2}

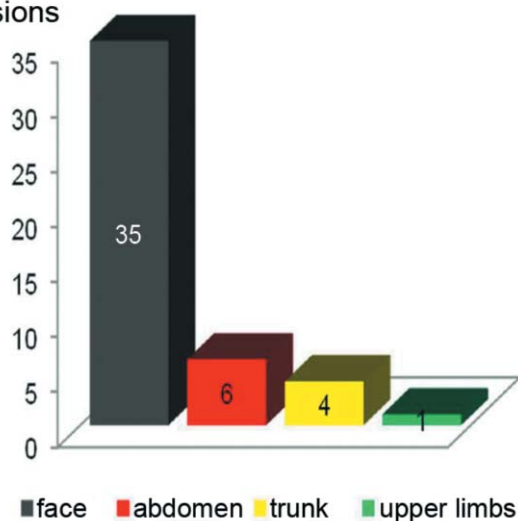
The use of ECA as a cutaneous adhesive is considered very safe due to its low rate of complications.^{1,2} The low infection rates have been attributed to the little deposition of foreign bodies into the wound.¹¹ Allergic reactions are rare.⁸ The ECA has some qualities common to other CAs, such as resistance to exudates, strength capable of enduring traction of up to 500 g, quick polymerization, and sealing, bactericide and haemostatic effects.^{5,10} Many studies have suggested increased use of ECA, despite the availability of other products supposedly less toxic, due to its distinct advantages over the other CAs, like lower cost, rapid degradation and wide availability.^{1,3,4}

On the present study the authors tried to observe various safety items in order to optimize the

TABLE 1: Sample definition, anesthetic type and technical details of the procedure

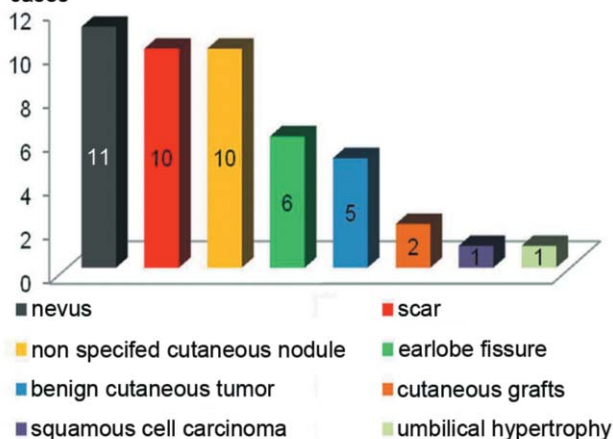
Patients seen		37	
number of lesions		46	excisions: 45 (97,8%) trauma: 1 (2,2%)
sex	females	89% (33)	
	males	11% (4)	
age		5 to 85 years old, average 38 years	
ASA		I: 84% (31)	
		II: 16% (6)	
anesthesia	local	97,3% (36)	
	local + sedation	2,7% (1)	
closing time/closing extension		1,2 min/cm to 8,3 min/cm, average: 3,0 min/cm	
closing extension		1,5 cm to 19,0 cm, average: 5,3 cm	

lesions



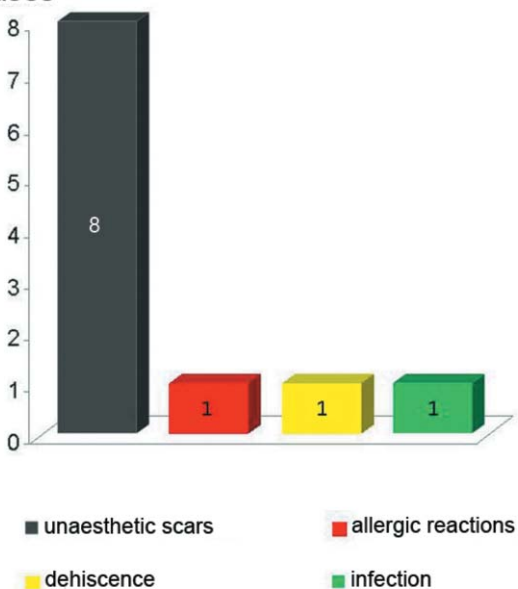
GRAPH 1: Distribution of the lesions

cases



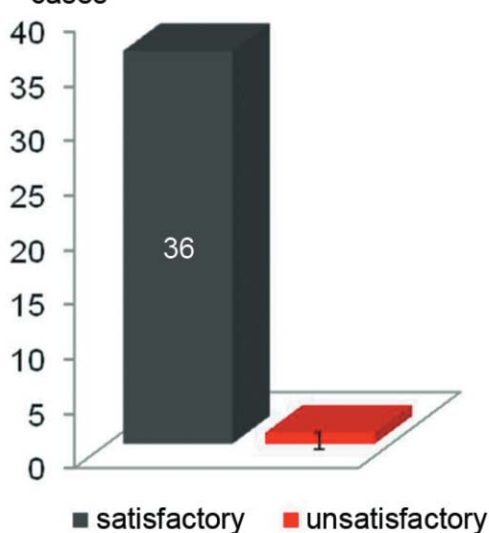
GRAPH 2: Diagnosis of the lesions

cases



GRAPH 3: Post-operative complications

cases



GRAPH 4: Aesthetic results according to the record of personal satisfaction from the patients

results. Psychotic and drug dependant individuals have a great chance of making unfounded questioning and of stopping the post-operative follow up. The itch and edema caused by local allergic reactions can predispose to the early removal of the CA plaques and, this way, to dehiscence. Diabetes mellitus, alcoholism, smoking, protein-caloric malnutrition, vitamin deficiency, and use of immunosuppressant drugs are associated with delayed healing.¹² According to the

distribution of the lesions, the present case series has confirmed that the CAs can be used successfully in wounds on any part of the body, except: (1) areas with very tight skin, like over articulations, unless relaxing deep sutures are placed, (2) in contaminated, exuding, bleeding or infected wounds, (3) is lesions subject to friction and humidity, like those on the soles, palms and in mucosa, as there might be a premature detachment of the adhesive and (4) allergy to CA or its

degradation products.^{1,2} Ultimately, a small surgery does not justify the decompensation of severe local or systemic diseases. The signing of the Free and Explained Consent Form is the legal registration that the candidate to any surgery is aware of its risks and benefits.

The average age and the predominance of women in this study reflect the individuals there are more frequently affected by the dermatosis, most of them caused by environmental hazards and surgical procedures. Experience has shown that most patients undergoing cutaneous excisions are 30 years or older when, conventionally, ageing starts.¹² From then on there is a gradual loss of integumentary trophism, which during youth constitutes an important component of social affirmation. Women pay higher tribute to society pressure,¹³ which has increasingly exploited the female beauty.

The lesions included in this investigation were those which resulted in an open area amenable to closure by direct sutures, under local anesthesia, without tension or distortion of neighboring structures. These characteristics included the restriction of the depth of the lesions to the skin and subcutaneous and a maximum of 3 cm width on the face and neck and 5 cm on the other areas of the body. We had great technical difficulty in closing intradermally/subdermally wounds with the longest dimension smaller than 0,5 cm. Therefore, they were repaired by simple sutures in a single level, and thus excluded from the present study. Antibiotics were not used for the surgeries, as there is evidence that antibiotic prophylaxis does not influence the occurrence of infection in clean or potentially contaminated ambulatory surgeries which last up to two hours.^{14,15}

Graphs 1 and 2 evidence the problems treated which were, mainly, benign facial nodules and post-surgical abdominal scars. With the exception of scars and earlobe tears, all the excisions were sent for histopathological examination. However, many patients did not have the examination and therefore many lesions removed had no diagnosis and were then registered as "non-specified cutaneous nodules".

Lidocaine has been the drug most used as an anesthetic in cutaneous infiltrations. In relation to marcaine, lidocaine has a bigger safety margin and its effects disappear earlier. The maximum dose of lidocaine used in this study was that recommended for small surgeries, which is 7 to 10 mg/Kg. If higher doses were needed the authors diluted the anesthetic up to a concentration of 0,25%. The risk of toxicity with this conduct is low due to the reduced anesthetic dose and the persistent vasoconstriction caused by the adrenaline.^{16,17} Adrenaline is a fundamental substance in anesthetic solutions. The usually recommen-

ded dose should not exceed 0,07 mg/Kg. It must be avoided in patients with *pheochromocytoma*, *hypertthyroidism*, severe high blood pressure, cardiopathy or peripheral arterial disease.¹⁷

Elliptical surgical excision is the most commonly employed technique in skin lesions. If the ellipsis is too short "dog ears" are formed, which are folds on the extremities of the suture. Dog ears do not disappear spontaneously; therefore they must be avoided by making the ellipsis two to three times longer than the width of the cutaneous lesion.¹² In keeping with this methodology, the biggest excision in our investigation was 5 cm wide, which resulted in a scar 15 cm long. We did not perform wider excisions due to the impossibility of closing the wound by direct suture.

The extension of the sutures that can be closed with CAs is broad. Lacerations and cutaneous incisions up to 50cm have been glued in a quick manner, with no clinical or statistical difference in terms of infection, dehiscence and appearance after 3 months, in relation to other traditional methods, like suture, stapling and adhesive tapes.^{1,2} The biggest closing performed on the present study was the one resulting from the excision of a xiphoid-pubic hypertrophic scar which was 17 cm in length and 0,5 cm in width, which resulted in a 19 cm scar, thus within the recommended limits.

In our surgical team the average speed of a suture, using single stitches placed at 2mm intervals is around 1 min/cm, therefore three times quicker than the one presented (3 min/cm). This longer time was due to the need for closing in three plans, as described: *subdermal*, including the reticular dermis, in order to promote relaxation of the borders of the lesion; *intradermal*, for sealing the cutaneous surface and prevent the leakage of the acrylate into the wound; and *epidermal*, by using the surgical adhesive (Figure 1). However, we noted that for closings of up to 5 cm in length the average additional time (10 minutes) was acceptable and counterbalances the benefits offered by the CAs. Besides, the smaller the wound and the best the training of the surgical team, the shortest the closing time.

The placing of a subdermal suture is indispensable. In the authors' experience, all the excisions closed with CAs only resulted in enlarged scars. This probably happens because the surgical glue links only the epidermal surface, like a bridge, which causes the sub-jacent dermis to gradually widen, resulting in a more exuberant scar at the late post-operative period.¹

Clinical and experimental works have suggested the use of commercial ECA in the closing of surgical wounds on the skin.^{1,3,6} In this case, before the use, special care must be taken with the sterilization of the CA. The package must be disinfected with ethylene

oxide and confirmed by means of cultures and no bacterial growth should develop on the external part.⁶ Microbiologic studies evidence the absence of bacterial proliferation on the non-sterilized adhesive.⁵

Despite the need for some training, the application of the CAs is relatively easy. The lesion must be dry and relaxed by detachment of the borders or deep sutures. A meticulous digital approximation of the borders is made and two to three fine layers of the adhesive are applied over and around the lesion (5 a 10 mm) with uniform movements. The squirt should be carefully squeezed in order to avoid leakage of the product into the wound. The patient's eyes must be protected with gauze if the application is close to them. In order to avoid premature loss of the adhesive, the following measures must be taken on the post-operative period: the wounds must be kept dry, although the lesions can be quickly dampened without being rubbed or soaped; swimming and any activity that cause intense perspiration must be avoided; dressings are not necessary; ointments or patches should not be placed directly over the adhesive.^{1,2}

On the present study, the CAs substantially eased the closing of the lesions. The application of the adhesive was simple and quick. When polymerized, the ECA formed a flexible, translucent, resistant and waterproof coating over the wound, without the need for stitches removal and use of dressings. This reduced the need for care, monitoring and use of anesthetics, resulting in lower costs. Besides, the product might be up to 4 times cheaper than suture, and 30 times cheaper than the octil-cyanoacrylate.¹ The patients were allowed to wet the sutures on the day following the repair. The adhesive was released completely, spontaneously, between 4 and 8 days. As the use of needles was spared, there were no risks of puncture accidents. The instantaneous polymerization made the early formation of a mechanical barrier which prevented the penetration of dirt and the loss of moisture in the wound available, shortening the surgical time, improving healing and leading to a quick keratinized epithelialization. These characteristics have been confirmed by the literature, so that currently the CAs are the closing method that most pleases the users.^{1,2}

Unaesthetic scars were the complications mostly associated with this study, occurring in 22% of the surgeries. There was a correlation between anatomic region and the type of healing: 63% of hypertrophic scars on the abdomen, as a result of excision of pre existent vertical laparotomy scars and 47% enlarged, on the face. These observations suggest that the hypertrophies were not due to the use of CA, but to local characteristics, like very movable skin, inflammatory reaction to subdermal relaxing sutures and closu-

res against the tension lines, factors undoubtedly fibrinogenic.¹² The unaesthetic scars were not attributed to the residual effect of the adhesive either, as the quick contact time of the CAs with the tissues can explain the smaller inflammatory reaction caused by the adhesives in relation to the suture.¹ Curiously, almost all the patients with unaesthetic scars (97,3%) were satisfied, as there was improvement of the appearance in relation to previously treated scars.

The total complication rate attributed by the authors directly to the effect of the ECA was 6,3% (one case of dehiscence (2,1%), one case of allergic contact dermatitis (2,1%) and one case of infection (2,1%)). The dehiscence occurred due to accidental premature removal of the adhesive film, resulting in partial opening of the wound (Figure 2D). Dehiscence is a constant worry when using CAs and it is considered the most common complication after histotoxicity, varying between 0,3% and 26% and occurring especially in wounds with irregular borders or traumatized, in lesions located on the extremities or in taught skin zones, without deep relaxing sutures.^{2,11} The use of CAs in wounds under high tension is contra-indicated, as this adhesive only provides the tensile strength of a 5-0 nylon suture.^{2,18}

One patient (2,1%) reported having, on the closing site, between the 2nd and the 5th post-operative day, a discrete inflammatory reaction compatible with contact allergic dermatitis, which completely receded on the 6th day. Allergic reactions to products containing ECA are virtually impossible due to their immediate polymerization over cornified surfaces. These components are unable to be sufficiently absorbed in order to induce significant allergic contact dermatitis, except if they applied directly in areas with thin skin, like the eyelids.⁸

The infection rate on the present study was similar to that reported on the literature researched (gluing: 2,1% x other methods: 1,1%).^{2,11} Some publications report infection rates in clean surgeries between 1,5% and 2,9%.¹⁵ The case in our study developed in a frontal excision and was characterized by contamination of the serous-sanguineous exudate which accumulated between the adhesive and the skin, which resulted in a superficial epidermal erosion, without dehiscence. The problem was treated with dressings, progressing with the formation of a linear scar with excellent cosmetic result. In clean wounds the reported infection occurrence is similar with CAs (0,7% x 1,1%), but in contaminated wounds the CAs have a pronounced bactericide effect.^{2,5,19} The exact mechanism is yet unknown, but it is probably related to the cellular wall, as the sensibility is restricted to gram positive bacteria, including *Staphylococcus aureus*. It is possible that the strong

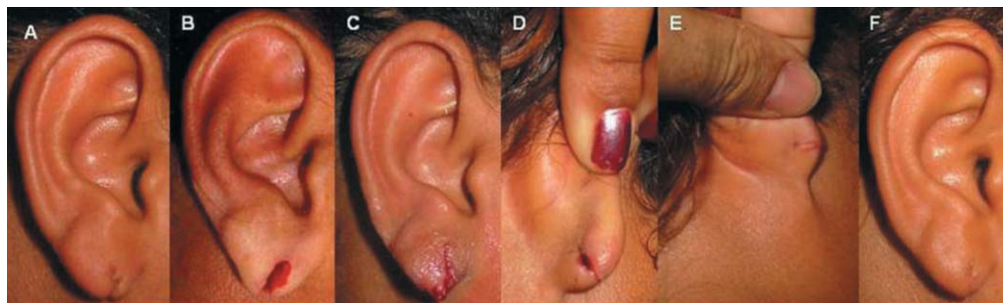


FIGURE 2: 33 year old patient with a right earlobe tear, 2,0 cm long, due to the use of earring. Pre-operative aspect (A), trans-operative (B), immediate post-operative (C), 7th day post-operative with partial dehiscence (D) and 3 month post-operative (E and F)

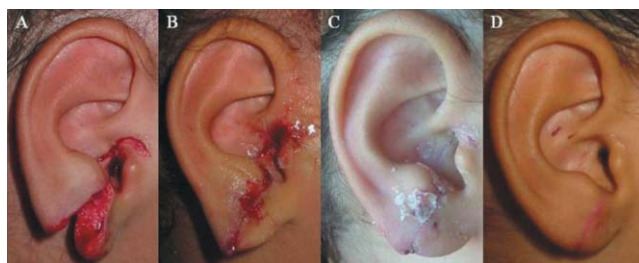

FIGURE 3: 5 year old patient with traumatic fissure of the right earlobe measuring 5cm in length. Pre-operative aspect (A), immediate post-operative (B), 7th day post-operative (C) and 3 month post-operative (D). The translucent plaques in C are residual fragments of ECA detaching spontaneously. Note in D a linear scar with perfect alignment on the inferior border of the earlobe

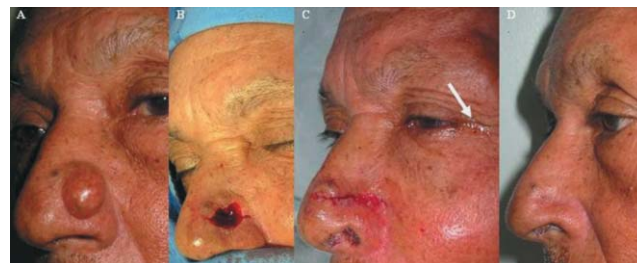

FIGURE 4: 65 year old patient sebaceous cyst on the nose, 1 cm in diameter. Pre-operative aspect (A), trans-operative (B), immediate post-operative (C) – arrow: lacrimation) and 3 month post-operative (D)

electronegative charge of the polymer reacts with the cellular wall of the gram positive bacteria which has a positive polar charge. Gram negative bacteria are relatively resistant, as their lipopolysaccharide membrane isolates the cellular wall. The CAs also avoid the deposition of foreign bodies into the wound, which potentiates their antibiotic effect. It has been shown that sutures decrease the amount of contamination needed to cause infection.¹⁹

This study confirmed that the ECA has a strong and unpleasant smell and it can be moderately irritating to the conjunctiva.^{1,20} In our patients, despite the fact that the eyes were covered with compress, a stinging sensation or lacrimation occurred in 67% of the gluing of periorbital (8 of 12 excisions). For this reason, we do not recommend the use of the product in this area.

The use of cutaneous adhesives is particularly useful in children. In many American and European pediatric centers, the use of CAs has been the first choice in the treatment of blunt wounds on the skin.⁹ On the study, the authors confirmed the particular advantages of the use of CAs in children, like the decreased use of anesthetic, no need of referral to surgical center, hospital admission and suture removal, especially on the face, all these contributing to decreased stress among infants (Figure 3).^{1,4,9,21}

In terms of aesthetic aspects, the CAs have demonstrated satisfactory results, similar to those obtained with sutures.^{1,2} The aspect of the scars remains the most important negative element when assessing cosmetic surgeries.²² The results from the present study agreed with this data. Only one patient (2,8%) was dissatisfied with the cosmetic result of the surgery, due to the adverse appearance of the surgical scar. Excellent results require adequate selection of the lesions to be treated and knowledge of the limitations and specific technical aspects of the adhesive in the closure of wounds. Clinical studies show that the use of the CAs on the skin has resulted in scars with aesthetic results similar to those of intradermal sutures.²

The absence of the most feared complication related to the use of ECA (necrosis), coupled with the high level of patient satisfaction (97,3%), were the most expressive results from this study. We interpret this as a strong suggestion of the safety of the use of ECA on the skin.¹ The use of the correct surgical technique, the external use in areas of the skin relaxed by subdermal sutures, the short term contact with the body surface and the use of minimum amount of the adhesive were the factors attributed to the good results at three months after the surgery. This result is predictive of one year.²³ Experimental works suggest that the necrosis induced by the CAs

CHART 1: ECA: advantages and disadvantages as cutaneous bioadhesive

ADVANTAGES	DISADVANTAGES
§ quick and easy application	§ little studied
§ quick closing of the skin	§ lacrimation
§ low cost	§ unpleasant smell
§ precludes anesthesia, dressing and stitches removal	§ risk of de histotoxicity
§ wide availability on the market	§ risk of allergic reactions
§ possibility of re-sterilization and repeated use	§ need for use of deep relaxing sutures
§ bactericide, haemostatic and sealing effect	§ use restricted to linear, non tense and only slightly bleeding wounds
§ absence of marks from stitches	
§ excellent aesthetic results	
§ great user satisfaction	

is restricted to the methyl-cyanoacrylate formulation.¹ However, although rare, the cutaneous necrosis by ECA is possible.⁷

CONCLUSIONS

The use of ECA was safe and had satisfactory cosmetic results in this group of patients, demonstrating various benefits in relation to the suture, including lower cost and reduced rates of complications (Chart 1). □

REFERENCES

1. Souza SC, Oliveira WL, Soares DF, Briglia CH, Athanázio PR, Cerqueira MD, et al. Comparative study of suture and cyanoacrylates in the skin closure of rats. *Acta Cir Bra*. 2007;22:308-15.
2. Singer AJ, Thode HC Jr. A review of the literature on octylcyanoacrylate tissue adhesive. *Am J Surg*. 2004;187:238-48.
3. Borba CC, Roubaud Neto E, Val RLR, Borba Jr CO, Soufen MA, Francisco Neto A, et al. Use of cyanoacrylate as surgical adhesive in rats skin incisions: experimental study. *Acta Cir Bras*. 2000;15:48-54.
4. Toriumi DM, Raslan WF, Friedman M, Tardy ME. Histotoxicity of cyanoacrylate tissue adhesives. A comparative study. *Arch Otolaryngol Head Neck Surg*. 1990;116:546-50.
5. Montanaro L, Arciola CR, Cenni E, Ciapetti G, Savioli F, Filippini F, et al. Cytotoxicity, blood compatibility and antimicrobial activity of two cyanoacrylate glues for surgical use. *Biomaterials*. 2001;22:59-66.
6. D'Assunção EA. Cola de cianoacrilato de baixo custo em cirurgia plástica. *Rev Soc Bras Cir Plast*. 2008;23:22-5.
7. Wang AA, Martin CH. Full-thickness skin necrosis of the fingertip after application of superglue. *J Hand Surg Am*. 2003;28:696-8.
8. Tomb RR, Lepoittevin JP, Durepaire F, Grosshans E. Ectopic contact dermatitis from ethyl cyanoacrylate instant adhesives. *Contact Dermatitis*. 1993;28:206-8.
9. Caloi TM, Manganello-Souza LC. Uso do cianoacrilato no fechamento cutâneo das queiloplastias primárias. *Rev Soc Bras Cir Plast*. 2005;20:108-11.
10. Tseng YC, Hyon SH, Ikada Y, Shimizu Y, Tamura K, Hitomi S. In vivo evaluation of 2-cyanoacrylates as surgical adhesives. *J Appl Biomater*. 1990;1:111-9.
11. Quinn J, Wells G, Sutcliffe T, Jarmusk M, Maw J, Stiell I, Johns P. A randomized trial comparing octylcyanoacrylate tissue adhesive and sutures in the management of lacerations. *JAMA*. 1997;277:1527-30.
12. Weinzeig J. Plastic surgery secret plus. 2nd. ed. Philadelphia: Mosby Elsevier, 2010.
13. Avelar JM. Contribuições à cirurgia plástica. São Paulo: Hipócrates; 2001.
14. Reese RE, Betts RF, Gumustop B. Manual de antibióticos. 3 ed. Rio de Janeiro: Guanabara-Koogan; 2002.
15. Dias GA. Antibioticoterapia profilática/ou terapêutica em pacientes submetidos à cirurgia plástica estética: uma necessidade? *Rev Soc Bras Cir Plast*. 2010;25:423-7.
16. Utiyama Y, Di Chiacchio N, Yokomizo V, Benemond TM, Metelmann U. Estudo retrospectivo de 288 lipoaspirações realizadas no serviço de dermatologia do hospital do servidor público municipal de São Paulo. *An Bras Dermatol*. 2003;78:435-42.
17. Iverson RE, Pao SV. MOC-PSSM CME article: Liposuction. *Plast Reconstr Surg*. 2008;121:1-11.
18. Bernard L, Doyle J, Friedlander SF, Eichenfield LF, Gibbs NF, Cunningham BB. A prospective comparison of octyl-cyanoacrylate tissue adhesive (Dermabond) and suture for the closure of excisional wounds in children and adolescents. *Arch Dermatol*. 2001;137:1177-80.
19. Quinn J, Maw J, Ramotar K, Wenkenbach G, Wells G. Octylcyanoacrylate tissue adhesive vs suture repair in contaminated wound model. *Surgery*. 1997;122:69-72.
20. Kine BB, Novak RW, Rohm; Haas Company. 2-Cyanoacrylics ester polymers. In: *Encyclopedia of Chemical Technology A to Alkanolamines*. 3rd ed. New York: John Wiley & Sons, Seaborg; 1978. p.408-13.
21. Souza SC, Briglia CH. Reparo de fissura de lóbulo auricular com cola cirúrgica de menor custo. *Rev Soc Bras Cir Plast*. 2010;25:715-8.
22. Ferreira MC. Cirurgia plástica estética - avaliação de resultados. *Rev Soc Bras Cir Plast*. 2000;15:61-6.
23. Blondeel PN, Murphy JW, Debrosse D, Nix JC 3rd, Puls LE, Theodore N, et al. Closure of long surgical incisions with a new formulation of 2-octylcyanoacrylate tissue adhesive vs commercially available methods. *Am Jour Surg*. 2004;188: 307-13.

MAILING ADDRESS:

Sandro Cilindro de Souza
 BR 101, Km 197, Caixa Postal 18
 44300-000 Cachoeira, BA
 Tel: (71) 9977-7303
 E-mail: sandrocilin@botmail.com

How to cite this article: Souza SC, Briglia C, Costa SRMR. Repair of cutaneous wounds with the use of low cost surgical glue. *An Bras Dermatol*. 2012;87(2):241-9.